

PATIENT

Oxford 59802752

SPECIES

Feline

BREED

Scottish Fold

SEX

Neutered Male

AGE

6 Months

WEIGHT

~7 Pounds

INTERPRETED BY

Eric Lindquist, DMV,
 DABVP (Canine & Feline), Cert. IVUSS

IMAGING PERFORMED BY

Greg Shaffer

HOSPITAL NAME

Saint Frances AC

REFERRING VET

Dr. O'Sullivan

INVOICE

35323

DATE

1/9/26

PRESENTING CLINICAL SIGNS

History: Chronic Diarrhea

Abnormal PE/Chem/CBC/UA Results: GI panel revealed Tritrichomonas, currently being treated with Tamidazole.

ULTRASONOGRAPHIC EXAMINATION OF THE ABDOMEN

Urinary System

The **urinary bladder**, trigone, and pelvic urethra presented normal thicknesses and normal tone. The ureters were not visible which is normal. No uroliths or sediment were visualized and a minimal amount of urine was present at the time of the sonogram. No evidence of inflammatory or neoplastic changes was noted. Ureteral papillae were normal.

The **kidneys** revealed normal size and structure, corticomedullary definition and ratio for this age. The cortices presented largely uniform texture with normal echogenic relationship to liver and spleen. Medullary structure differed distinctly from the cortex, and no evidence of pelvic dilation was present. The capsules were acceptably uniform without significant irregularities. The left kidney measured 3.54 cm. The right kidney measured 3.5 cm. Slight hyperechoic medullary rim sign and slight caudal pole collapse were noted in the right kidney. This may be a normal variant.

Adrenal Glands

The regions of the **adrenal glands** revealed no evident pathology.

Spleen

The **spleen** presented a smooth homogeneous parenchyma hyperechoic to liver and renal cortical parenchyma. The capsule was smooth without noticeable expansion or deviation from within the spleen or adjacent pathology. The splenic vasculature demonstrated normal volume without signs of congestion or thrombosis. No sonographic evidence of acute or chronic inflammatory, neoplastic, or infarctual changes were noted.

Liver

The **liver** images submitted revealed subjectively normal liver size, contour, and structure. Parenchymal echogenicity was naturally coarse and hypoechoic to the spleen. Vascular and biliary tracts were of normal volume with no evidence of congestion. The gallbladder presented acceptably thin walls with primarily anechoic content. The cystic and common bile ducts were normal. No pathological hepatic lymphadenopathy was evident. No overt structural evidence of inflammatory, infiltrative or regenerative pathology was evident.

Gastrointestinal

Examination of the **gastrointestinal tract** revealed a stomach and intestine free of stasis, of normal wall thickness, acceptable curvilinear mural detail, and peristaltic activity. Small intestine demonstrated normal luminal chyme. Soft stool was noted in the colon. No obstructive or overt infiltrative disease was noted. No associated abnormal lymphatic activity was noted.

Pancreas



PATIENT

Oxford 59802752

SPECIES

Feline

BREED

Scottish Fold

SEX

Neutered Male

AGE

6 Months

WEIGHT

~7 Pounds

INTERPRETED BY

Eric Lindquist, DMV,
 DABVP (Canine & Feline), Cert. IVUSS

IMAGING PERFORMED BY

Greg Shaffer

HOSPITAL NAME

Saint Frances AC

REFERRING VET

Dr. O'Sullivan

INVOICE

35323

DATE

1/9/26

The base and limbs of the **pancreas** were observed to be largely isoechoic to surrounding omental fat. Pancreatic duct and capsular contour were acceptably normal and parenchyma respected normal curvilinear patterns. No overt evidence of active inflammatory or neoplastic disease was noted.

Free Abdomen

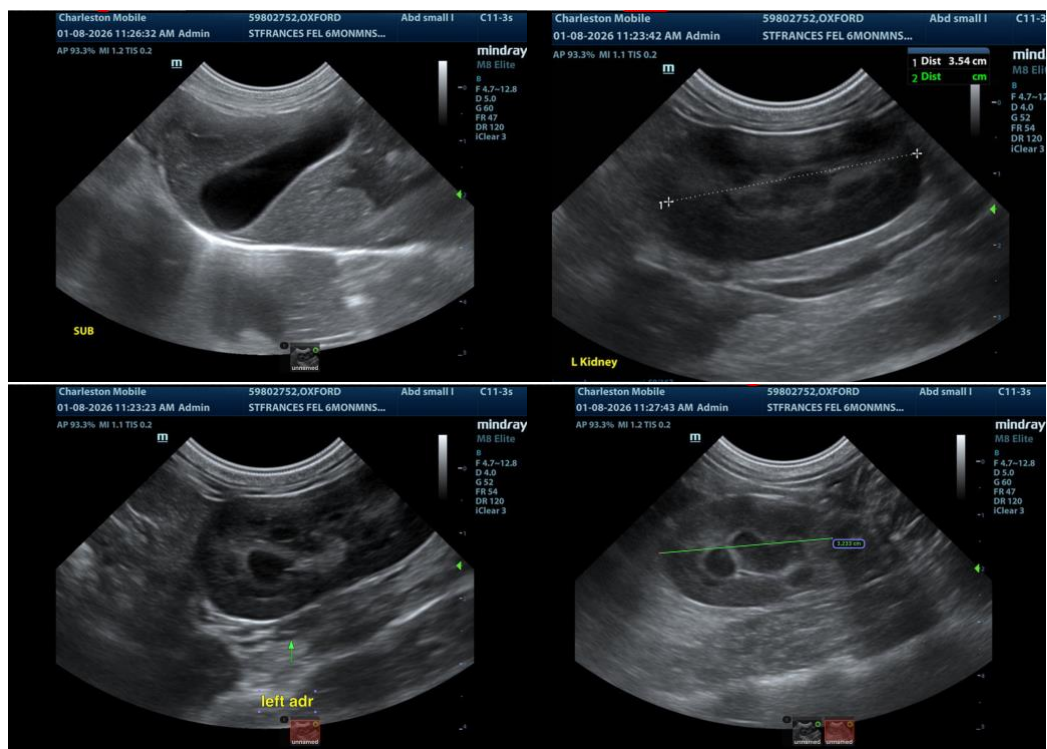
Mesenteric and colic **lymph nodes** were slightly enlarged and reactive.

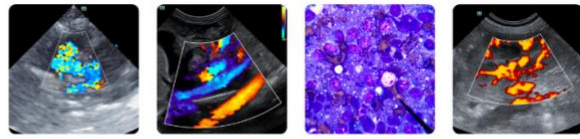
ULTRASONOGRAPHIC FINDINGS

- Structurally unremarkable abdomen
- Slight blunting of the caudal pole of the right kidney
- Slightly enlarged and reactive mesenteric and colic lymph nodes.

INTERPRETATION OF THE FINDINGS & FURTHER RECOMMENDATIONS

No evidence of pathology. Occult parasitism, dietary indiscretion, dietary intolerance, antibiotic responsive colitis, intestinal dysbiosis should all be considered as causes of diarrhea in this patient. A hydrolyzed diet trial may be in this patient's best interest +/- probiotics. 8-12-hour NPO and reintroduction of bland diet indicated. I recommend a fresh fecal smear and fecal floatation analysis if not already performed. Note that recent research has shown that indiscriminate use of antibiotics may actually cause harm. Most acute cases of diarrhea will respond to probiotic therapy, fiber, and gastrointestinal diets over the next 3-5 days. Low dose Prednisolone trial may be necessary in some cases. However, this may be problematic if an occult, non-evident round cell neoplasia or similar is developing.





PATIENT

Oxford 59802752

SPECIES

Feline

BREED

Scottish Fold

SEX

Neutered Male

AGE

6 Months

WEIGHT

~7 Pounds

INTERPRETED BY

Eric Lindquist, DMV,
 DABVP (Canine & Feline), Cert. IVUSS

IMAGING PERFORMED BY

Greg Shaffer

HOSPITAL NAME

Saint Frances AC

REFERRING VET

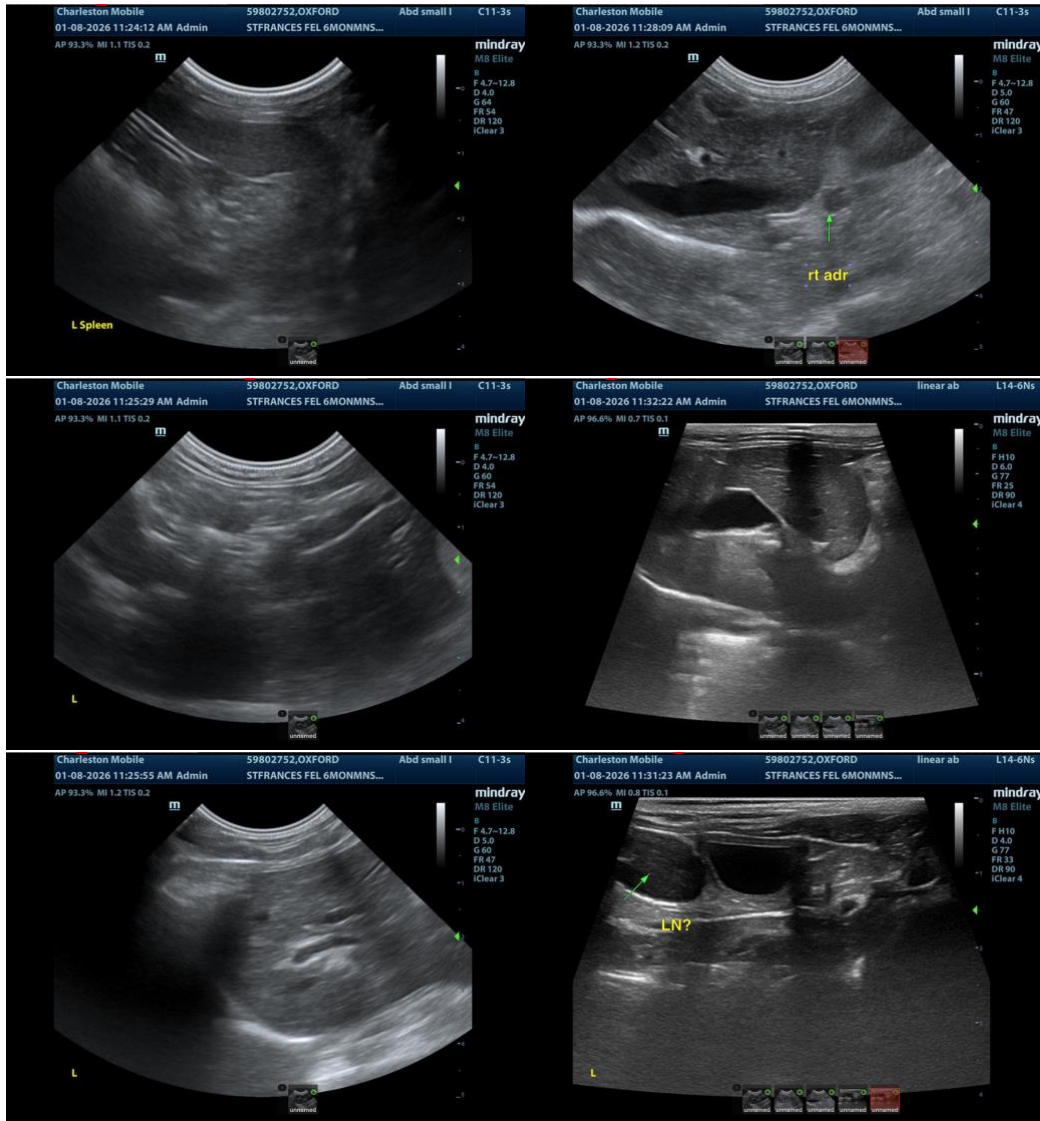
Dr. O'Sullivan

INVOICE

35323

DATE

1/9/26



The information and recommendations provided are based on the images presented by the referring veterinarian. No evaluation can be communicated regarding pathology that was not visible in the image/video clips provided.

Thank you for this referral. If the clinical or image interpretation does not parallel your findings or if I can be of any further assistance please contact me.

Eric Lindquist, DMV, DABVP, Cert. IVUSS, CEO of SonoPath.com

info@SonoPath.com